



PATIENT

Dakota Sabella

SPECIES

Canine

BREED

Greman Shephard
Mix

SEX

Male Neutered

AGE

6 years

WEIGHT

86lbs

INTERPRETED BY

Maggie Machen Lamy,
DVM, DACVIM
(Cardiology)

IMAGING PERFORMED BY

Kim Liedberg

HOSPITAL NAME

SVS Imaging WI

REFERRING VET

Dr. Thompson

INVOICE

28703

DATE

2/1/23

PRESENTING CLINICAL SIGNS

History: Presented for coughing. Suspect ITB. Treated with doxycycline with no improvement. Increased breathing rate at rest. No heart murmur noted on exam. On prednisone and cough tabs. Sedated with butorphanol.

RADIOGRAPHIC FINDINGS *NOTE: Images submitted for supplemental cardiac information only.
Cardiomegaly. Equivocal for CHF.

ELECTROCARDIOGRAPHIC FINDINGS *Note: Single lead ECGs are evaluated as a rhythm strip. Morphology/MEA cannot be definitively commented on.
A single lead ECG is available; 25mm/s, 10mm/mV. The average heart rate is 110bpm with a largely regular rhythm. The rhythm is sinus in origin, with a p for every QRS complex and vice versa. The P and QRS morphologies are positive. No ectopic beats, pauses or other dysrhythmias observed.

ECG diagnosis: Normal sinus rhythm with respiratory variation.

ECHOCARDIOGRAM FINDINGS

2D, m-mode, color flow and doppler imaging is available. Severe left ventricular dilation with decreased systolic function. Decreased LV wall thickness with increased sphericity. Severe left atrial enlargement. The mitral valve appears normal in form and function, with no obvious prolapse into the left atrial lumen. Mild mitral regurgitation secondary to annular stretch. Decreased velocity. Mild tricuspid regurgitation. Mild right atrial and ventricular dilation. TR velocity is normal. The aortic valve is normal in morphology and mobility. No subvalvular ridge present; normal LVOT velocity. No aortic insufficiency. Normal pulmonic valve with no pulmonic insufficiency seen. No pericardial or pleural effusion noted. No obvious cardiac tumors.

CARDIAC CHART

CANINE CARDIAC PARAMETERS	MR VMAX (m/s)	TR VMAX (m/s)	LA/AO (Boon method)	LA/AO (Heart Base; Swe)	FS (%)	EF (%)	EPSS (cm)
NORMAL PARAMETER	4.5-5.5	<2.7	1.3	<1.6	28-40	40-100	<0.6
PATIENT	4.6	2.0	NM	2.1	19	32	1.5
CANINE CARDIAC PARAMETERS	HR (BPM)	AV VMAX (m/s)	PV MAX (m/s)	BODY WEIGHT (kg)	LA 2D short axis Base view (cm)	LVIDd Avg; 2D and m-mode short axis (cm)	LVIDs Avg; 2D and m-mode short axis (cm)
NORMAL PARAMETER	50-100	0.7-1.7	0.7-1.6	BELOW	BELOW	BELOW	BELOW
PATIENT	86	1.6	0.9	39.0	5.1	6.6	5.3
*Normal chamber parameters expressed as a mean value (SD)				3	1.27 (5.3)	2.46 (2.46)	1.36 (5.5)
BODY WEIGHT DEPENDENT PARAMETERS				5	1.40 (4.5)	2.74 (5.2)	1.60 (4.7)
<i>*Note: All measurements based upon multi-modal images and methods. An average value is reported.</i>				10	1.50 (3.8)	3.27 (3.5)	2.06 (3.1)
				15	1.83 (2.0)	3.71 (2.4)	2.43 (2.1)
				20	2.02 (1.9)	4.14 (2.2)	2.80 (2.0)
				25	2.18 (2.4)	4.48 (2.9)	3.10 (2.5)
				30	2.33 (3.3)	4.83 (3.9)	3.39 (3.4)
				35	2.48 (4.3)	5.17 (5.0)	3.69 (4.5)
				40	2.62 (5.2)	5.48 (6.1)	3.96 (5.4)

Adapted from June Boon, Veterinary Echocardiography, 1998
Rishniw M and Hollis NE, J Vet Intern Med 2000; 14:429-435
Hansson et al, Vet Rad and Ultrasound 2002
Bonagura et al. Echocardiography: principles of interpretation, Vet Clin North Am 15:1177, 1995

**PATIENT**

50

2.88 (7.1)

6.07 (8.3)

4.46 (7.4)

Dakota Sabella

INTERPRETATION OF THE FINDINGS & FURTHER RECOMMENDATIONS

Unfortunately, this patient has significant cardiomyopathy and systolic dysfunction. This is causing dilation and volume overload of both the left and right heart resulting in insufficiency of the mitral and tricuspid valves. The severity of dysfunction and pump failure is high, and the patient is at high risk for decompensating into congestive failure. Patient will always be at risk for right and/or left-sided CHF, development of arrhythmias/syncope and/or sudden death going forward. The ECG is unremarkable with a normal sinus rhythm.

SPECIES

Canine

BREEDGremam Shephard
Mix

Systolic failure can be primary in nature (DCM) or secondary to taurine deficiency, myocarditis, hypothyroidism, tachycardia-induced cardiomyopathy, or infiltrative disease such as lymphoma. While primary disease is certainly possible, consider testing for primary causes that may be treatable. A troponin (cTnI) level can be submitted to further investigate infiltrative/inflammatory contribution (myocarditis). Additionally, a taurine level may be helpful (screen for malabsorption issue) and a thorough diet history given the recent correlation with grain free/boutique brand/exotic ingredient diets. Finally, further systemic evaluation for underlying infiltrative contribution such as neoplasia is also reasonable (abdominal ultrasound, etc.).

SEX

Male Neutered

AGE

6 years

Regardless of cause, prognosis is guarded to poor at this stage in the disease process, with an average survival time of <6 months. The only treatable cause of systolic failure is diet/taurine deficiency, which is uncommon on commercially formulated dog foods. If the diet is of concern, highly recommend immediate diet change and taurine supplement regardless of blood taurine results. Please see the FDA website for more information.

WEIGHT

86lbs

Immediate institution of full cardiac supportive medications is recommended as below due to high risk for decompensation and reported clinical signs. This includes low dose lasix therapy. Cases of systolic failure are at high risk for malignant tachyarrhythmias (such as VT or rapid AF) and sudden death, and this should be expressed to the owner. Activity restriction is advised. Baseline BP is recommended.

INTERPRETED BYMaggie Machen Lamy,
DVM, DACVIM
(Cardiology)

Elective anesthesia is not advised due to high risk for complications.

IMAGING PERFORMED BY

Kim Liedberg

Omega fatty acid supplementation and mild salt restriction may be of some long-term benefit. Monitor for development of a cough, worsening labored breathing, abdominal distention, exercise intolerance or collapse episodes in the future. Monitoring of sleeping breathing rates at home is recommended to assess response to medications and recurrence of CHF in the future.

HOSPITAL NAME

SVS Imaging WI

PLAN:

Baseline BP is recommended. Initiate aldosterone antagonist Spironolactone 1-2mg/kg PO q12h. Institute furosemide 1mg/kg PO q12h. Institute Pimobendan 0.3mg/kg PO q12h. Institute taurine 1000mg PO q12h. Diet history/change as discussed.

REFERRING VET

Dr. Thompson

Monitor a renal panel and blood pressure in 1-2 weeks to ensure tolerance. If BP >130mmHg, institute ACEI 0.5mg/kg PO q12h. Consider cTnI, taurine level, AUS as discussed above.

INVOICE

28703

A recheck echocardiogram is recommended in 4-6 months to screen for progression, sooner if clinical issues arise in the interim.

DATE

2/1/23

IMAGING PERFORMED BY

svsmobileimaging.com 309-737-3070



PATIENT

Dakota Sabella

SPECIES

Canine

BREED

Greman Shephard Mix

SEX

Male Neutered

AGE

6 years

WEIGHT

86lbs

INTERPRETED BY

Maggie Machen Lamy,
DVM, DACVIM
(Cardiology)

IMAGING PERFORMED BY

Kim Liedberg

HOSPITAL NAME

SVS Imaging WI

REFERRING VET

Dr. Thompson

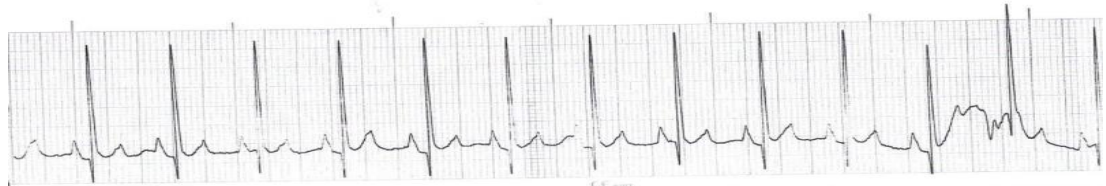
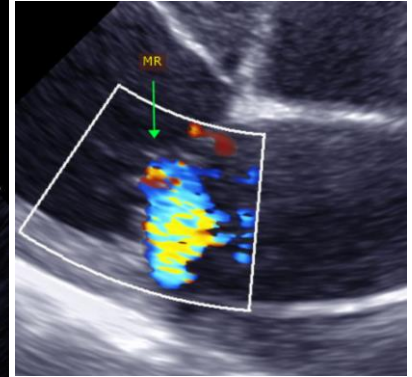
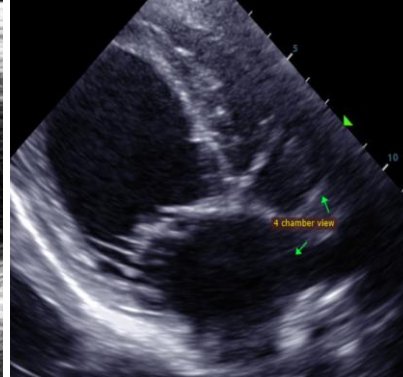
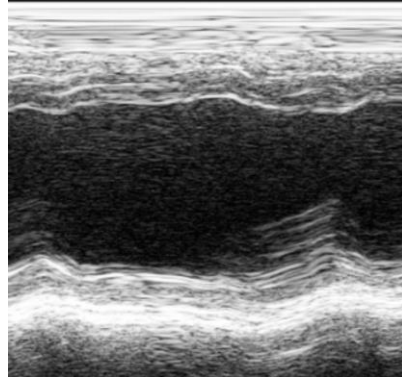
INVOICE

28703

DATE

2/1/23

IMAGES



The information and recommendations provided are based on the images presented by the referring veterinarian. No evaluation can be communicated regarding pathology that was not visible in the image/video clips provided.

Thank you for this referral. If the clinical or image interpretation does not parallel your findings or if I can be of any further assistance, please contact me.

Maggie Machen Lamy, DVM
Diplomate of the American College of Veterinary Internal Medicine (Cardiology)
info@sonopath.com